



PATIENT

Kammie Reed

SPECIES

Canine

BREED

Miniature Poodle

SEX

Female Spayed

AGE

14 years

WEIGHT

8.6lbs

INTERPRETED BY

Maggie Machen Lamy,
DVM, DACVIM
(Cardiology)

IMAGING PERFORMED BY

Sarah Pender, CVT

HOSPITAL NAME

SVS Imaging QC

REFERRING VET

Dr. Trammell

INVOICE

28458

DATE

1/19/23

PRESENTING CLINICAL SIGNS

History: History of intermittent chronic cough. No murmur ausculted.

-Pre-surgical EKG (Cardiopet): Indicated supraventricular arrhythmia most commonly seen with cardiac conditions leading to atrial enlargement. Possible atrial enlargement on thoracic radiographs.

RADIOGRAPHIC FINDINGS *NOTE: Images submitted for supplemental cardiac information only.
Mild cardiomegaly. No obvious evidence of CHF.

ELECTROCARDIOGRAPHIC FINDINGS *Note: Single lead ECGs are evaluated as a rhythm strip.
Morphology/MEA cannot be definitively commented on.

A single lead ECG is available; 25mm/s, 10mm/mV. The average heart rate is 120bpm (range 88-150bpm). The rhythm is sinus in origin, with a p for every QRS complex and vice versa. The P and QRS morphologies are positive. No ectopic beats, pauses or other dysrhythmias observed.
ECG diagnosis: Normal sinus rhythm with respiratory variation.

ECHOCARDIOGRAM FINDINGS

2D, m-mode, color flow and doppler imaging is available. Diffuse thickening of mitral valve leaflets with minimal prolapse into the left atrial lumen. Mild mitral regurgitation with mild left atrial dilation. Normal LV diameter with adequate myocardial function. The tricuspid valve appears mildly thickened with mild tricuspid regurgitation. Mild right atrial enlargement. TR velocity indicative of early pulmonary arterial hypertension. The pulmonic and aortic valves are normal in morphology and mobility. Normal pulmonic and aortic outflow velocities with laminar flow. No obvious aortic and trace pulmonic insufficiency. No pericardial or pleural effusion noted. No obvious cardiac masses.

CARDIAC CHART

CANINE CARDIAC PARAMETERS	MR VMAX (m/s)	TR VMAX (m/s)	LA/AO (Boon method)	LA/AO (Heart Base; Swe)	FS (%)	EF (%)	EPSS (cm)
NORMAL PARAMETER	4.5-5.5	<2.7	1.3	<1.6	28-40	40-100	<0.6
PATIENT	4.9	3.2	NM	1.4	46	80	0.22
CANINE CARDIAC PARAMETERS	HR (BPM)	AV VMAX (m/s)	PV MAX (m/s)	BODY WEIGHT (kg)	LA 2D short axis Base view (cm)	LVIDd Avg; 2D and m-mode short axis (cm)	LVIDs Avg; 2D and m-mode short axis (cm)
NORMAL PARAMETER	50-100	0.7-1.7	0.7-1.6	BELOW	BELOW	BELOW	BELOW
PATIENT	111	1.3	0.8	3.9	1.5	1.9	0.9
*Normal chamber parameters expressed as a mean value (SD)				3	1.27 (5.3)	2.46 (2.46)	1.36 (5.5)
BODY WEIGHT DEPENDENT PARAMETERS				5	1.40 (4.5)	2.74 (5.2)	1.60 (4.7)
*Note: All measurements based upon multi-modal images and methods. An average value is reported.				10	1.50 (3.8)	3.27 (3.5)	2.06 (3.1)
				15	1.83 (2.0)	3.71 (2.4)	2.43 (2.1)
				20	2.02 (1.9)	4.14 (2.2)	2.80 (2.0)
				25	2.18 (2.4)	4.48 (2.9)	3.10 (2.5)
				30	2.33 (3.3)	4.83 (3.9)	3.39 (3.4)
				35	2.48 (4.3)	5.17 (5.0)	3.69 (4.5)
				40	2.62 (5.2)	5.48 (6.1)	3.96 (5.4)
				50	2.88 (7.1)	6.07 (8.3)	4.46 (7.4)

Adapted from June Boon, Veterinary Echocardiography, 1998
Rishniw M and Hollis NE, J Vet Intern Med 2000; 14:429-435
Hansson et al, Vet Rad and Ultrasound 2002
Bonagura et al. Echocardiography: principles of interpretation, Vet Clin North Am 15:1177, 1995

**PATIENT**

Kammie Reed

SPECIES

Canine

BREED

Miniature Poodle

SEX

Female Spayed

AGE

14 years

WEIGHT

8.6lbs

INTERPRETED BYMaggie Machen Lamy,
DVM, DACVIM
(Cardiology)**IMAGING PERFORMED BY**

Sarah Pender, CVT

HOSPITAL NAME

SVS Imaging QC

REFERRING VET

Dr. Trammell

INVOICE

28458

DATE

1/19/23

INTERPRETATION OF THE FINDINGS & FURTHER RECOMMENDATIONS

Chronic degenerative valve disease causing mild mitral and tricuspid regurgitation. Mild biatrial enlargement indicates the current risk for complication is low. Mild pulmonary hypertension is noted with mild right atrial enlargement, which is likely developing secondary to the cough/airway disease in this predisposed breed. No concurrent issues such as systolic dysfunction are noted in this study.

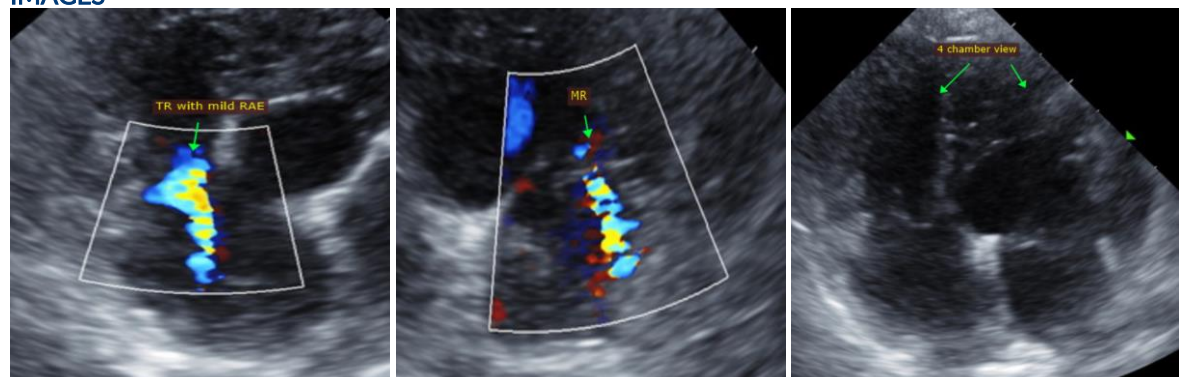
Given these findings, the cough is certainly non-cardiogenic in origin with respiratory disease considered most likely. If the cough is poorly controlled/progresses long term, this can certainly lead to worsening of PAH. Clinical signs of significant PAH include exertional dyspnea/collapse. Continued monitoring is advised. Cough control is recommended lifelong (hydrocodone, intermittent AI prednisone, fluoroquinolone for acute flare up, etc.).

The ECG is normal with no abnormalities identified. Presumably the prior tracing did show APCs, which appear to be infrequent. APCs can develop secondary to significant cardiac disease (mild in this study) or be extra-cardiac in origin, i.e., due to pain, stress, inflammation, cancer, GI disease etc. In a senior dog with mild disease, a combination is suspected. Consider systemic evaluation is indicated. Regardless, no therapy is indicated at this time and simple monitoring is recommended and simple monitoring is advised.

In a dog without significant left atrial enlargement, no cardiac medications are clearly indicated. Assessment of progression in the future will help predict long term prognosis, which is highly variable at this stage (B1). Omega fatty acid supplementation and mild salt restriction may be of some long-term benefit. Monitor for development of a cough, labored breathing, exercise intolerance or collapse episodes.

Anesthetic risk is considered mild if needed. Cardiac protective drug choices (opioid/benzodiazepine premedication, propofol or alfaxalone induction, isoflurane gas) are recommended. **Pre-oxygenate for 5-10 minutes prior to induction.** Monitor for arrhythmias, hypotension, and hypoxia both intra and post-operatively and intervene as necessary. Mild IV fluid restriction is recommended to avoid fluid overload. Avoid heart rate stimulating drugs such as atropine unless clinically indicated.

Recommend conservative monitoring with a recheck echocardiogram in 6 months, sooner if any development of clinical signs.

IMAGES

IMAGING PERFORMED BY

svsmobileimaging.com 309-737-3070



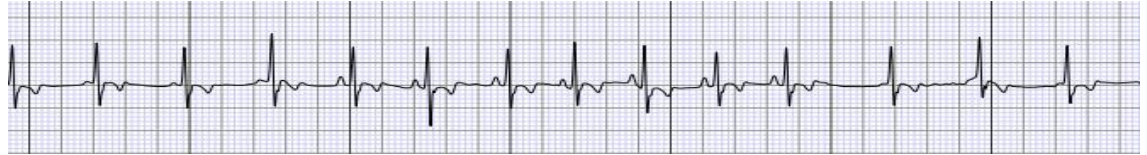Clinical Sonography & Telecytology

EDUCATIONAL TELECONSULTATION SERVICES™

1-800-838-4268 info@sonopath.com SonoPath.com

PATIENT

Kammie Reed



SPECIES

Canine

BREED

Miniature Poodle

SEX

Female Spayed

AGE

14 years

WEIGHT

8.6lbs

INTERPRETED BY

Maggie Machen Lamy,
DVM, DACVIM
(Cardiology)

IMAGING PERFORMED BY

Sarah Pender, CVT

HOSPITAL NAME

SVS Imaging QC

REFERRING VET

Dr. Trammell

INVOICE

28458

DATE

1/19/23

The information and recommendations provided are based on the images presented by the referring veterinarian. No evaluation can be communicated regarding pathology that was not visible in the image/video clips provided.

Thank you for this referral. If the clinical or image interpretation does not parallel your findings or if I can be of any further assistance, please contact me.

Maggie Machen Lamy, DVM
Diplomate of the American College of Veterinary Internal Medicine (Cardiology)
info@sonopath.com